

Diffuse stylohyoid chain ossification

Selma Uysal Ramadan, Dilek Gökharman, Mahmut Kaçar, Uğur Koşar

ABSTRACT

Clinical symptoms of stylohyoid chain ossification vary from ear pain to dysphagia. It is usually diagnosed coincidentally. Localized ossification of the chain is common, whereas diffuse ossification is rare. Herein, a case with bilateral diffuse stylohyoid chain ossification diagnosed with computed tomography, which was performed in order to evaluate the patient's temporomandibular joint pain, a rare onset of this condition, is discussed.

Key words: • temporomandibular joint • deglutition disorder • tomography, spiral computed

The bone and ligament complex that extends from the base of temporal bone styloid process to the minor horn of the hyoid bone is known as the stylohyoid chain. That chain shows many variations among populations, especially as styloid process elongation. Various clinical conditions, like dysphagia, tinnitus, jaw pain, and ear pain, may arise related to these variations and these symptoms usually delay diagnosis or are overlooked (1, 2).

Herein, a case with diffuse bilateral stylohyoid chain ossification diagnosed with computed tomography (CT), which was performed in order to evaluate the patient's temporomandibular joint pain, a rare onset of this condition, is discussed.

Case report

A 72-year-old male presented with long-lasting temporomandibular pain. On physical examination, the temporomandibular joint motion was natural, although there were questionable solid lesions bilaterally at the submandibular regions. CT examination of the joints was planned, as the major symptom of the patient was arthralgia. Laboratory findings were normal. CT examination of the temporomandibular joint did not reveal any specific findings that would clarify the cause of the chronic joint pain (Fig. 1). On the other hand, CT images indicated bilateral diffuse and thick ossifications of the stylohyoid chain (58 mm on the right and 57 mm on the left) extending from the styloid process to the minor horn of the hyoid bone. A gap was observed between the second and third sections of the chain where no ossification was evident (Fig. 2). As there was the presentation of a cortex and smooth margins on the edges of this gap, the possibility of fracture on the chain was not considered. No significant pathology in the adjacent neck structures was observed. Reassessing the history of the patient, his long-lasting dysphagia was striking. The case was considered to be inoperable because of his advanced age and he was given anti-inflammatory drugs palliatively. Partial resolution of his symptoms was achieved.

Discussion

The stylohyoid chain that extends between the temporal and hyoid bones is divided into 4 sections: the tympanohyal (the base of styloid process), the stylohyal (forms the major portion of styloid process), the ceratohyal (forms the stylohyoid ligament), and the hypohyal (forms the minor horn of the hyoid bone). The first 2 sections form the styloid process. Cartilage that is embryologically located at the stylohyoid ligament may undergo calcification of varying degrees, which causes variations. Ossified stylohyal ligament parts may merge or leave gaps in between. These ossifications may arise where the stylohyoid ligament attaches to the sty-

From the Department of Radiology (S.U.R. ✉ uysalselma@yahoo.com), Ankara Training and Research Hospital, Ankara, Turkey.

Received 22 August 2006; revision requested 28 October 2006; revision received 07 November 2006; accepted 5 December 2006.

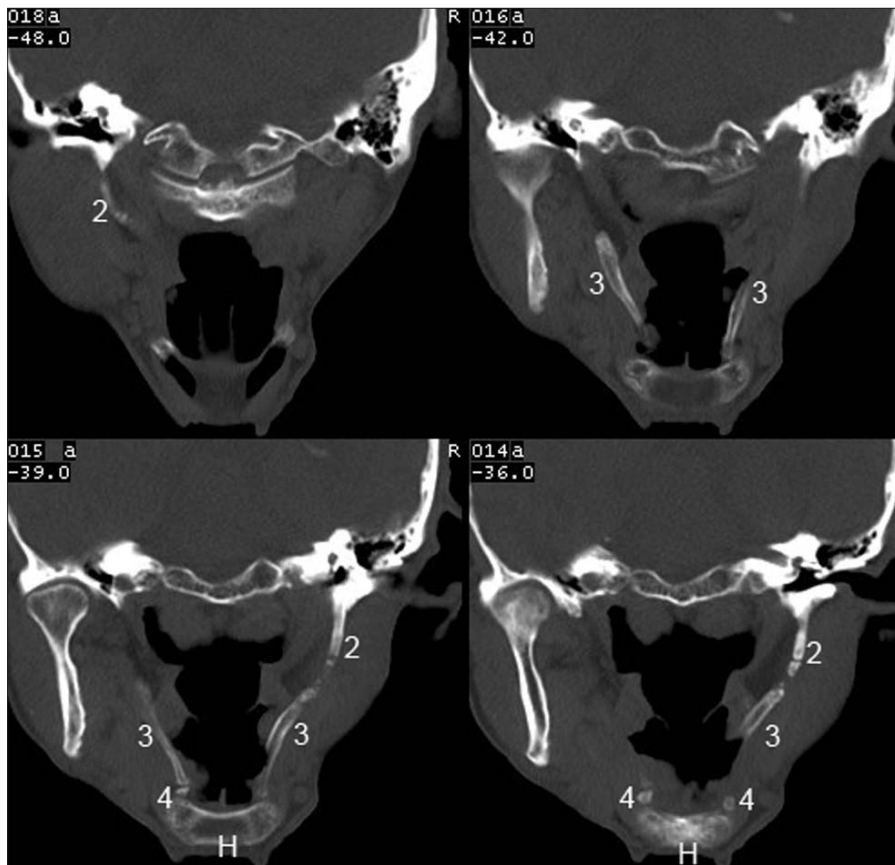


Figure 1. On coronal CT sections, it is possible to evaluate the parts of the stylohyoid chain bilaterally (2: tympanohyal and stylohyal segments; 3: ceratohyal segment; 4: hypohyal segment). Sections contain diffuse ossification extending towards the hyoid bone (H), and the gap in between.

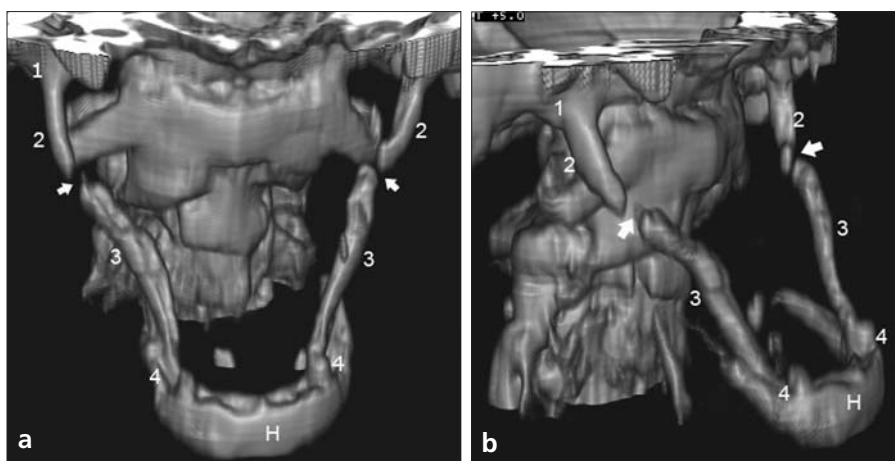


Figure 2. Anteroposterior (a) and oblique (b) 3D-CT images show ossification of the entire stylohyoid chain with a gap (arrows) between the second and third sections (1: tympanohyal segment; 2: stylohyal segment; 3: ceratohyal segment; 4: hypohyal segment; H: hyoid bone).

loid process due to unknown causes, such as osseous growth or trauma like tonsillectomy (3–7).

Palpation of a solid mass at the tonsillar fossa, pain at this region when pressure is applied, and pain relief after administration of local anesthetics are important diagnostic signs, but the ex-

act diagnosis of stylohyoid chain variations should be made using radiological examinations. Initially, panoramic X-ray, lateral cervical, or cranium and Towne radiographs have been used in order to evaluate this pathology, though it is not always possible to visualize the entire chain because of the su-

perimposition of the mandible or teeth (5, 8). Therefore, CT and 3D-CT can provide detailed information about both the chain itself and ossifications, as well as the possible relationship to adjacent structures like the carotid artery (2, 8).

As a result of advancements in examination methods, stylohyoid chain variations are diagnosed more frequently and commonly among the general population (6), and an elongated styloid process is the most common. Normal range of the length of styloid process and, thus, frequency of variations differ among the studies in literature (3, 9–11). While Eagle et al. reported the normal length of the styloid process as 2.5 cm and the rate of variation as 4%, other authors measured the length as 3 cm and the rate of variation as 21%–25% (9–12). It has been reported that it is probably symptomatic when the length of the process exceeds 4 cm (11). Furthermore, many variations, including absence of the styloid process, double styloid outlet, and localized or diffuse stylohyoid ossification, have been detected (8, 11). Correlations between these variations and age, sex, and symptoms were made in different studies and contradictory results were obtained (3, 7, 8, 11, 13).

It can be concluded that diffuse ossification of the stylohyoid chain is one of the rarest variations (1, 3, 8). In a study by Başekim et al. that included 138 patients, diffuse ossification was not encountered (8). Diffuse ossification differs from other variations as it affects the entire chain; thus, it may restrict head and neck motion. The mechanism by which head motion remains unaffected is probably related to non-ossified regions on the chain, or the fracture of the ossified chain at its weakest point during movement or trauma (3, 4, 7, 14, 15). In particular, if a patient history includes trauma, it can be difficult to distinguish fractures of the segmentary ossified chain or non-ossified regions between the ossified sections. Usually, pain caused by fractures is not clinically significant because of accompanying major trauma (7). In case of displacement or pseudoarthrosis at the fracture site, diagnosis becomes easier while using direct X-ray images or CT, although CT would more accurately discriminate in such conditions. Visualization of the cortex at the edges of the bone, and a smooth

and fusiform cortical surface helps to eliminate chain fracture as a diagnostic possibility (14, 15).

In conclusion, radiological evaluation of the stylohyoid chain in patients with non-specific symptoms, or with indistinct clinical and laboratory findings, may help clinicians to more accurately diagnose the situation.

References

1. Kay DJ, Har-El G, Lucente FE. A complete stylohyoid bone with a stylohyoid joint. *Am J Otolaryngol*. 2001; 22:358–361.
2. Savranlar A, Uzun L, Uğur B, Özer T. Three-dimensional CT of Eagle's syndrome. *Diagn Interv Radiol* 2005; 11:206–209.
3. Gözil R, Yener N, Çalgüner E, Araç M, Tunç E, Bahçelioğlu M. Morphological characteristics of styloid process evaluated by computerized axial tomography. *Ann Anat* 2001; 183:527–535.
4. Murtagh D, Carracciolo JT, Fernandez G. CT findings associated with Eagle syndrome. *AJNR Am J Neuroradiol* 2001; 22:1401–1402.
5. Prasad KC, Kamath MP, Reddy KJM, Raju K, Agarwal S. Elongated styloid process (Eagle's syndrome): a clinical study. *J Oral Maxillofac Surg* 2002; 60:171–175.
6. Krennmair G, Piehslinger E. Variations of ossification in the stylohyoid chain. *J Craniomandib Prac* 2003; 21:31–37.
7. Vougiouklakis T. Overview of the ossified stylohyoid ligament based in more than 1200 forensic autopsies. *J Clin Forensic Med* 2006; 13:268–270.
8. Başekim Ç, Mutlu H, Güngör A, et al. Evaluation of styloid process by three-dimensional computed tomography. *Eur Radiol* 2005; 15:134–139.
9. Eagle WW. Elongated styloid process. *Arch Otolaryngol* 1948; 47:630–640.
10. Kaufman SM, Elzay RP, Irish EF. Styloid process variation radiologic and clinical study. *Arch Otolaryngol* 1970; 91:460–463.
11. Monsour PA, Young WG. Variability of the styloid process and stylohyoid ligament in panoramic radiographs. *Oral Surg Oral Med Oral Pathol* 1986; 61:522–526.
12. Mortellaro C, Biancucci P, Picciolo G, Vercellino V. Eagle's syndrome: importance of a corrected diagnosis and adequate surgical treatment. *J Craniofac Surg* 2002; 13:753–758.
13. Jung T, Tschernitschek H, Hippen H, Schneider B, Borchers L. Elongated styloid process: when is it really elongated? *Dentomaxillofac Radiol* 2004; 33:119–124.
14. Blomgren K, Ovarnberg Y, Valtonen H. Spontaneous fracture of an ossified stylohyoid ligament. *J Laryngol Otol* 1999; 113:854–855.
15. Smith G, Cherry JE. Traumatic Eagle's syndrome. *J Oral Maxillofac Surg* 1988; 46:606–609.